

JOSEPH A. JACHIMCZYK, M.D., J.D.
FORENSIC PATHOLOGIST
ATTORNEY AT LAW
CHIEF MEDICAL EXAMINER



994.7
E963

228-8311
EXT. 671 (DAY)
EXT. 212 (NIGHT)

OFFICE OF THE MEDICAL EXAMINER
OF HARRIS COUNTY

HARRIS COUNTY COURT HOUSE
HOUSTON, TEXAS 77002

AUTOPSY REPORT

Case 73 - 3413

August 15, 1973

PATHOLOGICAL DIAGNOSIS ON THE BODY

OF

Billy Gene Baulch, Jr.
439 West 16th Street
Houston, Texas


Asphyxia due to strangulation.

OPINION

It is our opinion that the decedent, Billy Gene Baulch, Jr., came to his death as a result of asphyxia due to strangulation - Homicide.

It is our further opinion that death occurred on or about May 21, 1972.

COMMENT: In view of the above, it is our opinion, based upon a reasonable medical probability, these are the remains of Billy Gene Baulch, Jr.



Joseph A. Jachimczyk, M.D., J.D.
Chief Medical Examiner

(See Companion Cases 73-3365, 73-3366, 73-3408, 73-3409 and 73-3412)

POSTMORTEM EXAMINATION ON THE BODY OF

Billy Gene Baulch, Jr.
439 West 16th Street
Houston, Texas

HISTORY: These skeletal remains were recovered in Chambers County, approximately 1917 feet east of the West County line of Chambers County, Texas, approximately 123 feet south of Highway 87, at approximately 4:00 p.m. on August 13, 1973. This body and 73-3412 (Unknown #25) were atop one another in a common grave with their respective heads at opposite ends of the grave. The grave appeared to be about 36 inches deep, 24 inches wide and 42 inches in length. There was no lime-like substance or noticeable foreign matter in the grave, other than the remains of this body and 73-3412 (Unknown #25), a cord similar to a venetian blind cord and plastic covering. This body, according to the Sheriff at the scene, had a smaller bone structure than that of 73-3412 (Unknown #25). (See Companion Cases 73-3365, 73-3366, 73-3408, 73-3409, and 73-3412)

AUTOPSY: The autopsy was performed by Chief Medical Examiner Joseph A. Jachimczyk, M.D., assisted by Assistant Medical Examiners Ethel E. Erickson, M.D., and G. Sheldon Green, M.D., and assisted by Dr. Paul G. Stimson, beginning at 4:30 p.m. on August 15, 1973, in the Harris County Morgue.


EXTERNAL APPEARANCE: Received in a black crash bag were the skeletal remains of a human being with the flesh nearly completely deteriorated away, but covered with mud and lime. Included was a length of looped cord, venetian blind type, that was wrapped around the neck. The head was covered with brown hair, measuring up to 6 to 7 inches in length. Also included was a length of thicker rope, that was about twice the thickness of the venetian blind cord, with a hangman's noose in it. Included was the skull; the mandible was not present. Two femurs were present. Two tibias were present. Two humeri, two fibulas, two ulnas and three radii were present. One of these radii probably belongs to Case 73-3412. Two clavicles, two scapulae, two pelvic bones, eighteen ribs, one metatarsal and twelve vertebrae. The length of the femur was 17 inches; the length of the tibia was 14 inches; the length of the fibula was 14 inches; humerus was 12 inches; ulna 9-1/2 inches and radius 10-1/2 inches. The clavicles each measured 6 inches in length.

Further examination of these remains revealed the following bones: skull intact; the mandible is absent; cervical vertebrae 1 and 2, and 4 or 5; four mid thoracic vertebrae; five lumbar vertebrae, these represented lumbar vertebrae from two skeletons. There was no lumbar vertebra 5 present. Four of the vertebrae were intact. One lacked the entire neural arch. The appearance of this bone suggested a congenital lesion as in a spina bifida. All of these vertebrae showed some degree of fusion of the annular epiphyses. Three, including that with the possible spina bifida, were similar in the shape of their centra to the shape of the centra of the sacrum and appeared to match with the remainder of the skeleton. The two remaining lumbar vertebrae did not appear to be consistent with these remains and were removed. Also present were the left ilium, complete, sacrum, complete, right and left scapulae, right ribs 1, and 3 through 11, numbers 2 and 12 were missing, left ribs 2, 3, and 4 and 6, 7, 8, 9, and 11, numbers 1, 5, 10 and 12 were missing, right and left clavicles, right and left femurs, right and left tibia, right and left fibula, right and left humeri, showing stage 3 fusion of the proximal epiphyses and stage 4 fusion of the distal conjoint epiphyses and medial epicondalar epiphyses.

The following bones were present, which were not consistent with this skeleton: a right ilium; this showed stage 0 fusion of the epiphysis of the iliac crest. The symphysis pubis was consistent with an age in the mid teens and up to 18 years; right ribs 9, 10 and 11; these were substantially more massive than the remainder of the ribs and clearly did not belong with this skeleton; two right ulnas, both showing stage 4 fusion of the proximal epiphyses and stage 0 fusion of the distal epiphyses; one left ulna, showing stage 4 fusion of the proximal epiphyses, and stage 2 to 3 fusion of the distal epiphyses; a left 5th metatarsal; and a right hamate. The last two bones could not definitely be linked to this skeleton, nor can they be totally eliminated from it. However, in the absence of definitive evidence of belonging to it, they were removed to a separate container to be labeled as having been found with this skeleton, but not consistent with it.

DENTAL EXAMINATION

Dental examination reveals the maxilla only; the mandible is not present with the remains. The upper right and left third molars are in the crypts. There is distal occlusal caries on the upper right second molar, which is tooth 2. There is distal occlusal caries on the upper right first molar, tooth 3. There is distal occlusal caries on the upper left first molar, which is tooth 14. There is occlusal caries on the upper left second molar, which is tooth 15. There is an incisal chipping and wear on tooth 9, towards the distal incisal. Tooth 9 has a mesial rotation with a mesial incisal angle lapped over the mesial incisal angle of tooth 8.



Paul G. Stimson, D.D.S., M.S.

SUPPLEMENTAL REPORT

October 8-9, 1973

Mrs. Baulch, together with Barbara Jo Cox, was at the Harris County Morgue between 9:30 a.m. and Noon on October 8, 1973, and was shown photographs of all of the clothing. She did not identify any items from the clothing on that day. Mr. Knowles, however, noticed a visible reaction when she looked at the silver belt buckle. She was then shown the hair display of the victims and said that Unknown #26 was similar to the hair of Billy, but Unknown #2 was too light to be similar to the hair of Michael. She was then shown three photographs of Unknown #2. She said she was unsure, but that it might be Michael. She was then shown the jaws of Unknown #2. She looked at them and stated that she could not be sure, but it could be Michael's mouth. Prior to this, however, she described a chip in tooth #9 and a vertical crack in tooth #8 on Michael.

She was then shown the maxilla of Unknown #26. When she saw the teeth in the anterior posterior view and then when the maxilla was being rotated so that she could have a headon look at the teeth numbers 8 and 9, she exclaimed "That's Billy's teeth" and broke into tears. After comforting her for approximately twenty minutes, we then asked her to look again at the maxilla and mandible of Unknown #2 and she said that that could be Michael, but she was not sure. She requested that her husband be permitted to see what she was shown this date. In fact, her niece, Barbara Jo Cox, called Mr. Baulch and spoke with him on the telephone. I also spoke with Mr. Baulch on the telephone and we made a date for him to come in with Mrs. Baulch between 8:00 and 8:30 a.m. on October 9, 1973.

Between 8:30 and 10:30 a.m. on October 9, 1973, Mr. Baulch was shown the same items. Initially, he thought that the hair of Unknown #2 was not quite coarse enough to be that of Michael, but that the hair of Unknown #26 could be Billy. He then looked at the photographs and he recognized the silver buckle and the belt to which it was attached as being his which he gave to Michael to wear. He was then shown the buckle and the belt, and he examined them very carefully, and both he and Mrs. Baulch agreed that that was the belt that Michael wore. Mrs. Baulch also stated how she cut the end of the

belt off to make it fit Michael. Mr. Baulch mentioned the stretching in the backside and demonstrated that. He demonstrated the sag in the backside of the belt and explained the reason for it happening, namely he being a truck driver sitting in that position for long intervals of time. He was then shown the same photographs of the Unknown #2 body taken during the autopsy and was not quite sure at that point whether it was Michael or not. He was then shown the maxilla of Billy first and he agreed with his wife's statement that this was Billy's mouth. He was then shown the maxilla and mandible of Unknown #2 and stated that that looked like it, but that he could not be positive immediately. He studied the teeth more fully. He, as well as Mrs. Baulch, remembered a crack in tooth #8, running the vertical length of the tooth. He related as to the manner of how he sustained that injury, when he jumped off and struck his chin against his knee and cracked his tooth. He also recognized the attrition resultant from the grinding habit that Michael was known to have. Both parents mentioned this even before we showed them the teeth. He then studied the smile by cupping his hands over the jawbones and looking only at the teeth and decided that yes that was Michael.

Finally, at their request, they were shown all of the autopsy photographs of Unknown #2, including the two gunshot holes, and at this point, each parent agreed it was Michael and that was Michael's hair. Accordingly, the body of Unknown #2, Michael, and the skeletal remains of Unknown #26, Billy Baulch, were made ready for release to the Heights Funeral Home, which was the wish of the parents. The funeral services were scheduled for 10:30 a.m. on October 12, 1973.


Mrs. Baulch also pointed out that the canines of Billy were real pointed and the canines on Michael were more worn and flat. This conforms to the appearance of these teeth in Unknown #2 and Unknown #26.

SUPPLEMENTAL REPORT

October 11, 1973

Following the identification of the dental features of this decedent as being those of Billy Baulch, it was evident that the estimate of age, based upon the features of the left innominate bone, were not consistent with the age of this decedent. The right innominate bone, which was originally removed from these remains, was consistent with an age of 17 years and clearly must have belonged to this decedent. The sacrum fit the older left innominate bone and did not fit the younger right innominate bone. Therefore, the left innominate, the sacrum, and three lumbar vertebrae which more closely matched the configuration of the sacrum, were removed from these remains. The right innominate was placed in the container together, with two lumbar vertebrae which were more consistent with a slightly larger, heavier individual than was represented the now unidentified left innominate. Re-examination of the long bones of the forearms showed that all three ulnas were consistent with an age in the mid teens. Two of them, a right and left, provided reasonable matches, at the elbow joint, for the two humeri. The two radii matched in length, configuration and general bone structure with these two ulnas and also provided a reasonable fit at the elbow joint. They were now included with the remains of Billy Baulch.

Thus, the unidentified skeletal parts which were removed from this body consisted of a left innominate, a sacrum, three lumbar vertebrae, including that which showed failure of fusion of the neural arch, three ribs, a hamate bone, and a fifth metatarsal. The maxilla which had been preserved in a separate container, was now added to the remains of Billy Baulch at this time.



G. Sheldon Green, M.D.

Autopsy

INVESTIGATOR'S REPORT

Investigator: H. C. Gregory

~~View~~

Case No. 73 - 3413

Decedent: Billy Gene Baulch, Jr. Race W Sex M Age 17

Address: 439 West 16th Street, Houston, Texas

Death: FOUND August 13, 1973 Approx. Time 4:00 ~~XXXX~~
P.M.

Place of Death: Chambers County, approximately 1917 feet east of the West County
line of Chambers County, approximately 123 feet south of Hwy. 87

Place of Inquest: _____

Date and Time of Inquest: August 14, 1973 4:50 ~~XXXX~~
P.M.

Location, Position, and Surroundings of Body:

This common grave was known as Chambers County Grave Site #4.
This body was known as Chambers County Body #5.

Clothing: There was no clothing.

Information:

The decedent, according to Chambers County Sheriff Louis Otter, was disinterred from a grave site at the above location at the above time. The grave appeared to be about 36 inches deep, 24 inches wide and 42 inches in length. There was no lime-like substance or noticeable foreign matter in the grave, other than the remains of Medicolegal Case 73-3412 and Medicolegal Case 73-3413, a cord similar to a venetian blind cord and plastic covering. The decedent, according to Sheriff Otter, had a smaller bone structure than that of Unknown #25 (Case 73 - 3412). The decedent and Case 73-3412 (Unknown #25) were atop one another in a common grave with their respective heads at opposite ends of the grave.

H. C. Gregory
H. C. Gregory *HN*

(See Companion Cases 73-3365, 73-3366, 73-3408, 73-3409 and 73-3412)

Property: No jewelry, buttons, buckles or personal effects were located in the grave.

Transferred to Morgue by: Sterling Funeral Home, Dayton, Texas

Funeral Home Conducting Service: Heights Funeral Home, Houston, Texas

SUPPLEMENTAL
INVESTIGATOR'S REPORT

Autopsy

Investigator: H. C. Gregory

~~View~~

Case No. 73 - 3413

Decedent: _____ Race _____ Sex _____ Age _____

Address: _____

Death: _____ Approx. Time _____ A.M.
P.M.

Place of Death: _____

Place of Inquest: _____

Date and Time of Inquest: _____ A.M.
P.M.

Location, Position, and Surroundings of Body:

Clothing:

Information:

The following information was furnished on August 13, 1973, by Houston Police Department Homicide Detective Donovan regarding Billy Baulch, 17 year old white male, 5 feet 9 inches, 145 pounds, 439 West 16th Street, Houston, Texas. Billy Baulch had been missing since May 21, 1972. The suspect Brooks said that Billy Baulch was one of the decedents. Billy Baulch had a chip in his upper left lateral incisor. An X-ray of Billy Baulch's left elbow will be furnished to this department, revealing a fracture which occurred in 1966.

X-ray labeled "Billy Baulch" and a black and white photograph of Billy and Mike Baulch were turned over to H. C. Gregory at the Harris County Morgue on August 13, 1973, by Houston Police Department Officers A. J. Toepoel and E. E. Benningfield.

H. C. Gregory
H. C. Gregory *HN*

Property:

Transferred to Morgue by:

Funeral Home Conducting Service:

1. PLACE OF DEATH a. COUNTY Chambers		2. USUAL RESIDENCE (Where deceased lived. If institution: residence before admission) a. STATE TEXAS b. COUNTY HARRIS	
b. CITY OR TOWN (If outside city limits, give precinct no.) (found) Approx. 1917 ft. E. of the W. 1/2 Sec. 8. of Twp. 87		c. CITY OR TOWN (If outside city limits, give precinct no.) Houston	
d. NAME OF (If death in hospital, give street address) HOSPITAL OR INSTITUTION County line of Chambers Co./ approx./		d. STREET ADDRESS (If rural, give location) 439 West 16th	
e. IS PLACE OF DEATH INSIDE CITY LIMITS? YES <input type="checkbox"/> NO <input type="checkbox"/>		f. IS RESIDENCE ON A FARM? YES <input type="checkbox"/> NO <input checked="" type="checkbox"/>	
3. NAME OF DECEASED (Type or print) [a] First BILLY [b] Middle GENE [c] Last BAULCH, Jr.		4. DATE OF DEATH Found 8-13-73	
5. SEX Male	6. COLOR OR RACE White	7. Married <input type="checkbox"/> Never Married <input checked="" type="checkbox"/> Widowed <input type="checkbox"/> Divorced <input type="checkbox"/>	8. DATE OF BIRTH April 21, 1955
9. AGE (In years last birthday) 18		IF UNDER 1 YEAR Months Days	IF UNDER 24 HRS. Hours Minutes
10a. USUAL OCCUPATION (Give kind of work done during most of working life, even if retired) Student		10b. KIND OF BUSINESS OR INDUSTRY School	
11. BIRTHPLACE (State or foreign country) Houston, Texas		12. CITIZEN OF WHAT COUNTRY? USA	
13. FATHER'S NAME Billy Baulch, Sr.		14. MOTHER'S MAIDEN NAME Maggie Jane Cox	
15. WAS DECEASED EVER IN U.S. ARMED FORCES? (Yes, no, or unknown) No		16. SOCIAL SECURITY NO. ---	
17. INFORMANT			
18. CAUSE OF DEATH [Enter only one cause per line for (a), (b), and (c).] PART I. DEATH WAS CAUSED BY: IMMEDIATE CAUSE (a) Asphyxia due to strangulation.			INTERVAL BETWEEN ONSET AND DEATH
Conditions, if any, which gave rise to above cause (a), stating the underlying cause last. } DUE TO (b) _____ DUE TO (c) _____			
PART II. OTHER SIGNIFICANT CONDITIONS CONTRIBUTING TO DEATH BUT NOT RELATED TO THE TERMINAL DISEASE CONDITION GIVEN IN PART I (a)			19. WAS AUTOPSY PERFORMED? YES <input checked="" type="checkbox"/> NO <input type="checkbox"/>
20a. ACCIDENT <input type="checkbox"/> SUICIDE <input type="checkbox"/> HOMICIDE <input checked="" type="checkbox"/>		20b. DESCRIBE HOW INJURY OCCURRED. (Enter nature of injury in Part I or Part II of Item 18.) Strangled.	
20c. TIME OF INJURY Hour found Day 8 Year 13 73 UNK a.m. p.m.			
20d. INJURY OCCURRED WHILE AT WORK <input type="checkbox"/> NOT WHILE AT WORK <input checked="" type="checkbox"/>		20e. PLACE OF INJURY (e.g., in or about home, farm, factory, street, office building, etc.) (found) Chambers County	
20f. CITY, TOWN, OR LOCATION Chambers		STATE Texas	
21. I hereby certify that I attended the deceased from found to _____, 19____ and last saw the deceased alive from autopsy findings on _____, 19____. Death occurred at 8-13-73 m. on the date stated above, and to the best of my knowledge, from the causes stated.			
22a. SIGNATURE Joseph A. Jachimczyk, M.D.		22b. ADDRESS 209 Courthouse Houston, Texas	
22c. DATE SIGNED 10-17-73			
23a. BURIAL, CREMATION, REMOVAL (Specify) Burial		23b. DATE October 12, 1973	
23c. NAME OF CEMETERY OR CREMATORY Woodlawn Garden of Memories			
23d. LOCATION (City, town, or county) Houston		24. FUNERAL DIRECTOR'S SIGNATURE HEIGHTS FUNERAL HOME	
25a. REGISTRAR'S FILE NO.		25b. DATE REC'D BY LOCAL REGISTRAR	
25c. REGISTRAR'S SIGNATURE			

TEXAS DEPARTMENT OF HEALTH — BUREAU OF VITAL STATISTICS

MEDICAL CERTIFICATION

VS-112, REV. 1/68

994.7
E963

2413

Unit #26

RECORD OF IDENTIFICATION PROCESSING
SKELETAL CHART

ML 73-3413

LAST NAME - FIRST NAME - MIDDLE INITIAL (or unknown number)

BLACK OUT PORTIONS NOT RECOVERED

GRADE SERVICE NUMBER

NAME OF CEMETERY, EVACUATION NUMBER, OR SEARCH AND RECOVERY NUMBER

PLOT ROW GRAVE

ESTIMATED AGE (Years) ESTIMATED HEIGHT
21-23 63 1/2 - 66 inches

SKELETAL MEASUREMENTS (Centimeters)

SKELETAL MEMBER	METHOD	SKELETAL MEASUREMENTS (Centimeters)	
		RIGHT	LEFT
SKULL			
HUMERUS			
ULNA			
RADIUS			
FEMUR			
TIBIA			
FIBULA			

REMARKS OR STATEMENT OF ANTHROPOLOGIST (Continue on reverse if more space is required)

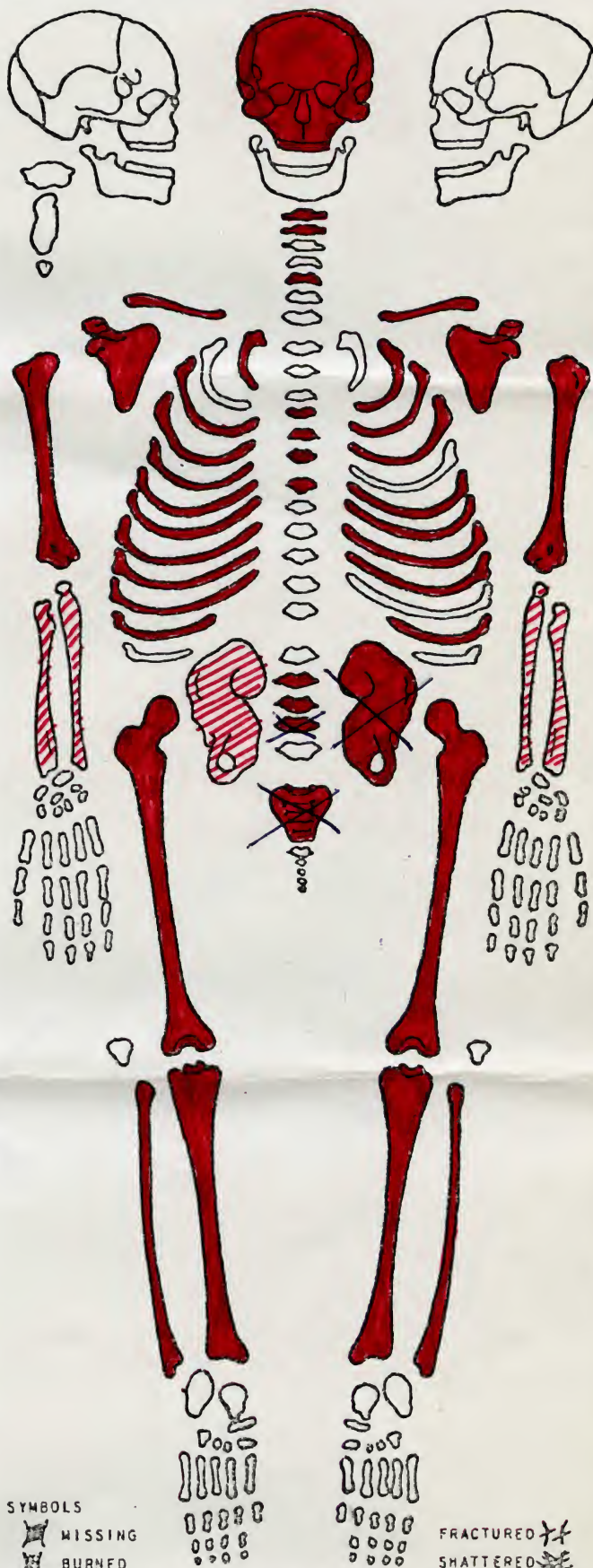
Dorsal arch of one lumbar vertebra missing.
- symmetrical - possible spina bifida?

10-11-73 Note (1) Age based on l. pelvis does not fit this decedent, Age of right pelvis is consistent with age 17. Correct pelvis placed & remains this date. (2) Radius & ulna (R & L) added this date. Bone structure, size & elbow articulation fit this body. See dictated note this date.

THE PARTS PRESENT AS INDICATED ON THIS SKELETAL CHART REPRESENTS ONE AND THE SAME INDIVIDUAL

PHYSICAL ANTHROPOLOGIST (Name)

SIGNATURE



SYMBOLS
 [Red hatched box] MISSING
 [Red hatched box with star] BURNED
 [Red hatched box with cross] FRACTURED
 [Red hatched box with star and cross] SHATTERED

STATE HIGHWAY PATROL

DENTAL CHART

Fill out all information in PENCIL

26

_____ Assigned identification number	_____ Division Case Number
<u>73-3413</u> Autopsy number	_____ Picture Pouch Number
_____ Armed Forces Serial Number	_____ Date of Exam.
_____ Social Security Number	_____ Place of Exam.

(Circle One) UNKNOWN

PRESUMPTIVE BY EXCLUSION

CONFIRMED

Name of the Deceased	Estimated Age	Race	Sex
<i>Billy Baulch</i>			

CONFIRMED IDENTIFICATION OF BODY BY _____
Name of Examiner

Confirmed identification by means of (circle) X-ray comparison, Clinical conformation by previous dental records, Other _____

X-rays taken (circle one) None, Complete Mouth, Bite Wings, Other _____

Photographs taken (circle one) None, Color, Black & White, Other _____

Name, Address, and Telephone Number of Photographer _____

Location of the Body _____

Position of the Body _____

BEFORE PROCEEDING—READ PAGE 2 CAREFULLY AND FOLLOW ALL INSTRUCTIONS—HAVE A QUALIFIED ASSISTANT TO DO ALL RECORDING
RECORD ALL INFORMATION IN PENCIL

Name, Address, and Telephone Number of the Examiner _____

Name, Address, and Telephone Number of the Assistant _____

Signature of the examiner _____

Signature of the Assistant _____

DENTAL CHARTING PROCEDURES

Tooth surfaces are recorded as follows—Mesial-M, Distal-D, Buccal-B, Occlusal-O, and Lingual-L.

Indicate if crowned tooth are Porcelain, Plastic, Gold, Gold Veneer, or non-precious metal. Write in above appropriate tooth on restoration chart—Page 3. For Gold work or veneer crowns outline restoration and indicate gold with parallel vertical lines. For porcelain crowns or plastic fillings outline restorations only—write in the type of material. For all amalgam and non-precious metals black in. (SEE EXAMPLE BELOW)

This charting procedure starts with the upper right third molar which is tooth #1 and proceeds around the arch. The upper right central incisor is #8, the upper left third molar is #16. The lower left third molar is #17. The lower right central incisor is #25 and the lower right third molar is #32.

Mark all deciduous teeth with a D around the number of its permanent successor. The deciduous upper right central would be marked **8** and the lower right second deciduous molar would be marked **29**.

EXAMPLE OF HOW TO PROCEED WITH DENTAL CHARTING

	1	2	3	4	5	6	7	8	9	10	11	12	13	14	15	16	
UPPER RIGHT																	UPPER LEFT
	1. O-AM	2. DOL-AM; F-AM	3. MOD GOLD FILL	4. F-GOLD FILL; ML-AM	5. MO-AM	6. ML-GOLD FILL	7. 3/4 GOLD CR	8. D-PORC FILL	9. PORC-CR	10. F-PORC FILL; L-AM	11. MF-PORC FILL	12. PX-POSTHUMOUSLY MISSING	13. GOLD-CR	14. MISSING	15. MO-AM; L-AM	16. MODL-AM	

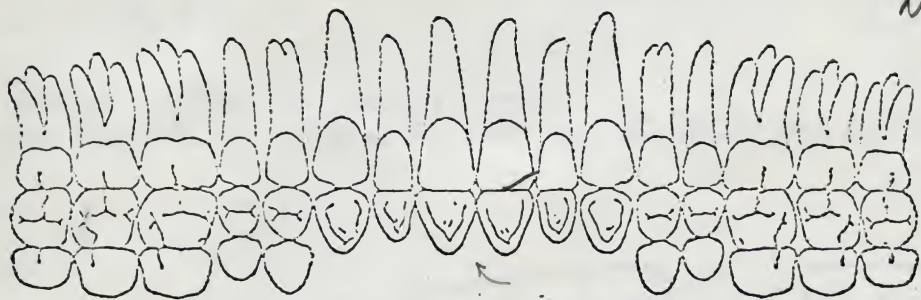
After you have finished your examination have your assistant read the charting back to you as you recheck each tooth; then proceed to note any of the following conditions. Indicate answers with tooth number.

- | | |
|-----------------------------------|---------------------------------|
| Hottled Enamel _____ | Rotation _____ |
| Fractured Enamel _____ | Irregularity of Alignment _____ |
| Enamel Hypoplasia _____ | Unerupted Tooth _____ |
| Fractures of Tooth _____ | Unusual Restorations _____ |
| Erosion _____ | Malocclusion _____ |
| Retained Dec. Teeth _____ | Unusual Appliances _____ |
| Abrasion _____ | Supernumerary Tooth _____ |
| Abnormal Interdental Spaces _____ | Malposed Tooth _____ |

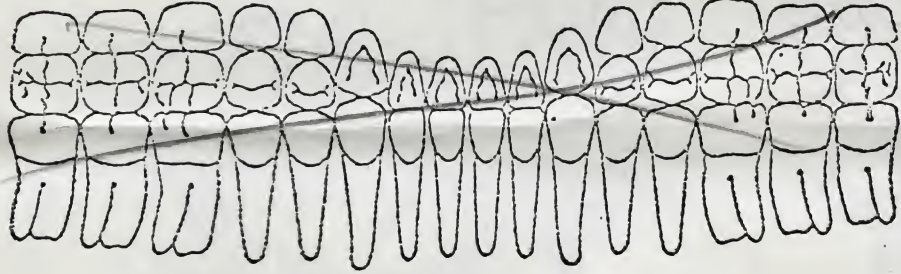
REMARKS _____

MARK ALL RESTORATIONS ON THIS CHART

NO FILLINGS



RIGHT 1 2 3 4 5 6 7 8 9 10 11 12 13 14 15 16 LEFT
32 31 30 29 28 27 26 25 24 23 22 21 20 19 18 17



Circle descriptive term

Prosthetic Appliances Present — Maxilla

Full Denture

Partial Denture
Fixed Bridge

Prosthetic Appliances Present — Mandible

Full Denture

Partial Denture
Fixed Bridge

Describe completely all Prosthetic Appliances or

Fixed Bridges NO MANDIBLE #9 CHIPPED ON DISTAL INCISAL

#9 MESIAL ROTATION - LAPS OVER MESIAL INCISAL OF #8

Stains on teeth

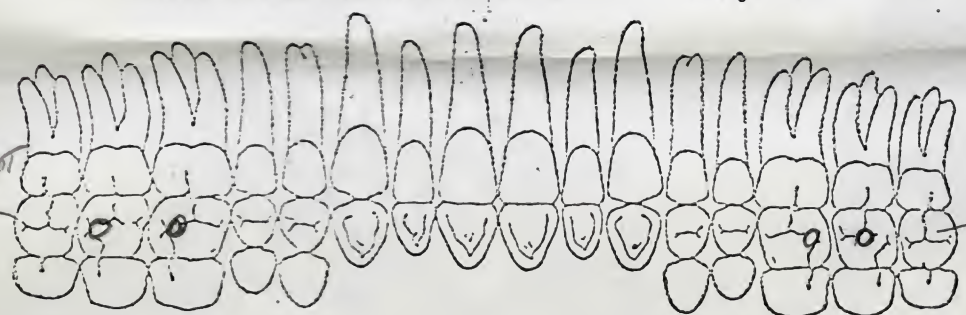
Slight

Moderate

Severe

MARK ALL CARIES AND MISSING TEETH ON THIS CHART

Outline all caries and 'X' out all missing teeth



RIGHT 1 2 3 4 5 6 7 8 9 10 11 12 13 14 15 16 LEFT
32 31 30 29 28 27 26 25 24 23 22 21 20 19 18 17

Circle descriptive term

Jaw Relationship

Normal

Undershot

Overbite

Periodontal condition

Excellent

Average

Poor

Gross Neglect

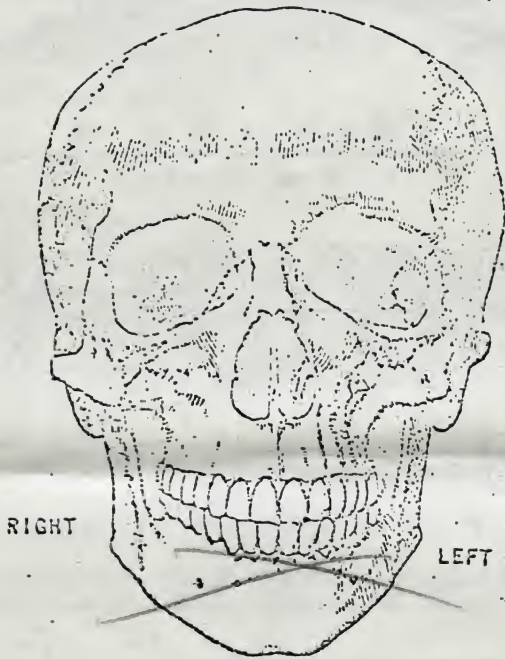
Calculus

Slight

Moderate

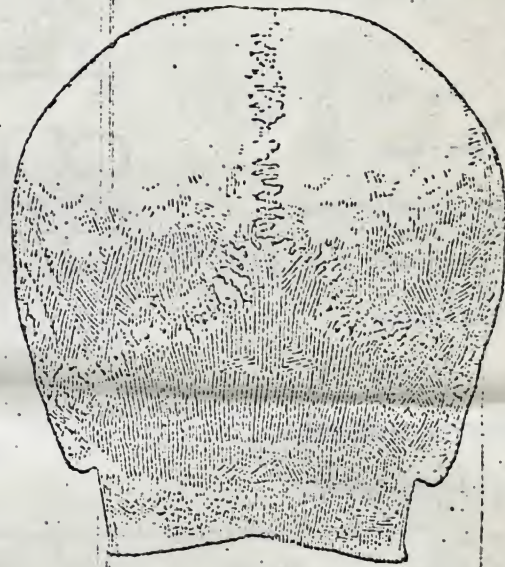
Severe

ANATOMICAL OUTLINES

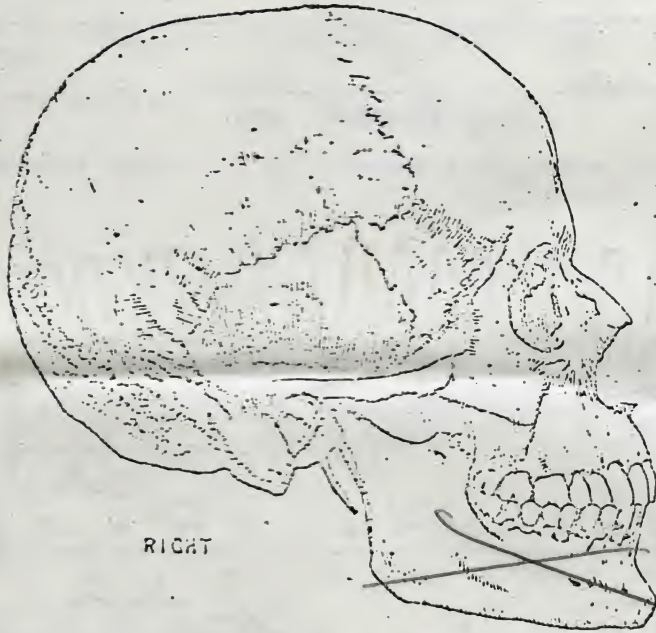


LEFT

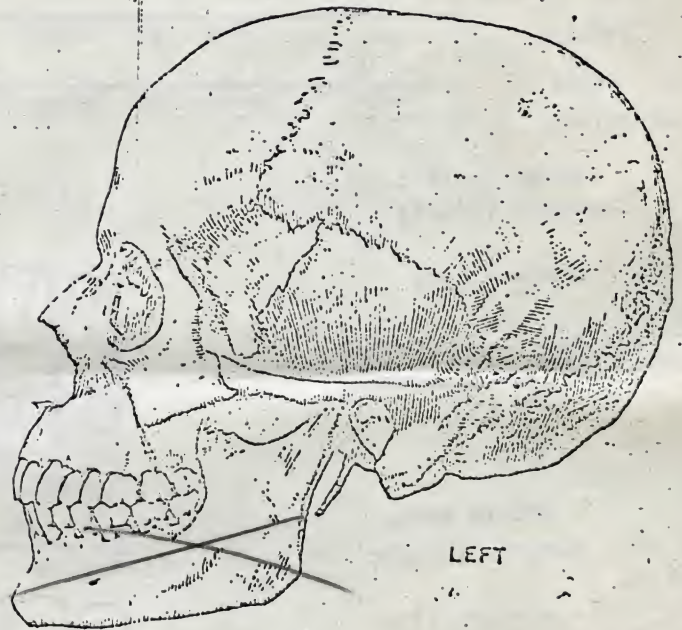
RIGHT



ENTIRE SKULL AVAILABLE FOR EXAMINATION _____ YES, _____ NO.
 IF ONLY PARTS OF THE SKULL ARE AVAILABLE BLACK OUT THE PARTS OF THE SKULL THAT YOU HAVE
 USED FOR THE IDENTIFICATION PROCEDURE. MARK IN ALL LINES OF FRACTURE.



RIGHT



LEFT

MAKE SURE THAT ANY PARTS OF THE SKULL THAT YOU REMOVE HAVE ATTACHED TO THEM A TAG
 WITH THE ASSIGNED IDENTIFICATION NUMBER.

AFIP NUMBER 65-5346-1

Division Consultant: Dr. Curtis A. Hartz
 P. O. Box 370
 Ashtabula, Ohio 44004

BODY CAN BE VIEWED: YES _____
NO _____

DATE: _____

26

ML 73-3413

SEX: _____

SCARS: Skeleton

RACE: _____

TATTOOS: _____

EST. AGE: 21-23

OTHER: poss. spina bifida of one lumbar vertebra

HEIGHT: 5-3/2 to 5-6

X-RAY: _____

WEIGHT: _____

CLOTHING: None

EYES: _____

PERSONAL EFFECTS: _____

HAIR: brown 6-7 inches

DECEDENT'S NAME: _____

DECEDENT'S ADDRESS: _____

NEXT OF KIN: _____

ADDRESS: _____

IDENTIFIED BY: _____ DATE: _____

ADDRESS: _____

HCME OFFICER PRESENT: _____